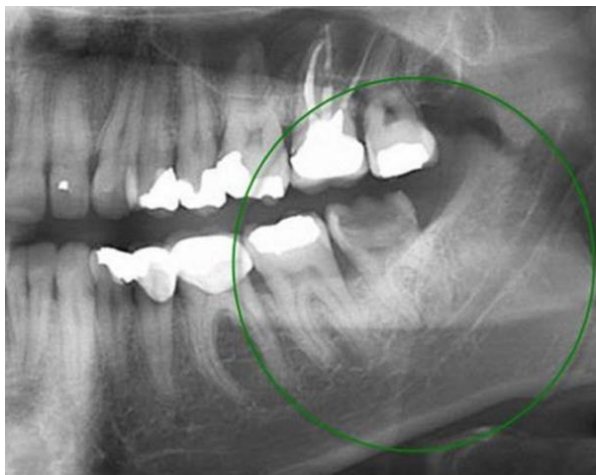

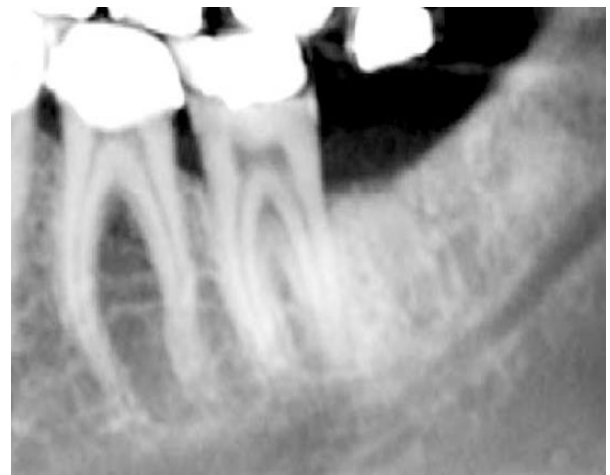Grafting for socket preservation

Case description: Male, 34 years old. Extraction of the tooth #38 and immediate grafting with autologous dentin prepared from roots.

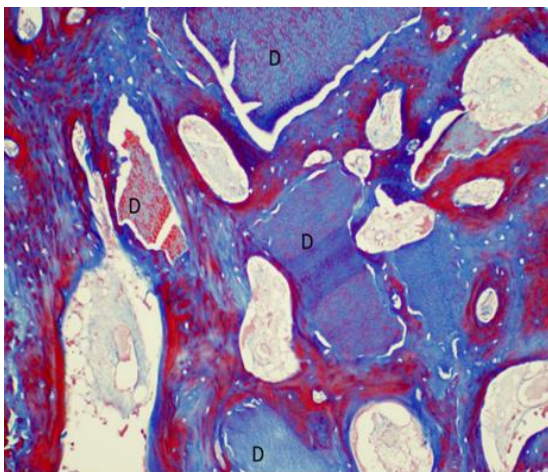
Results: Bone-dentin ankylosed tissue is formed from autologous graft of dentin root particulate. High stability of bone ridge.



Before extraction

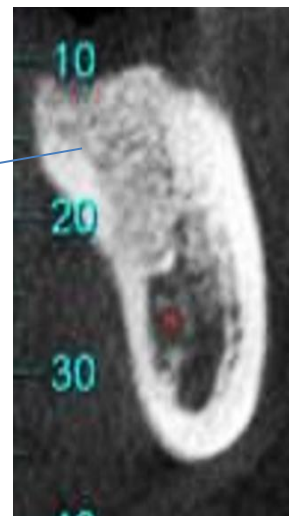


After extraction and grafting



CT imaging of Dentin bone interface

← biopsy



One year after grafting