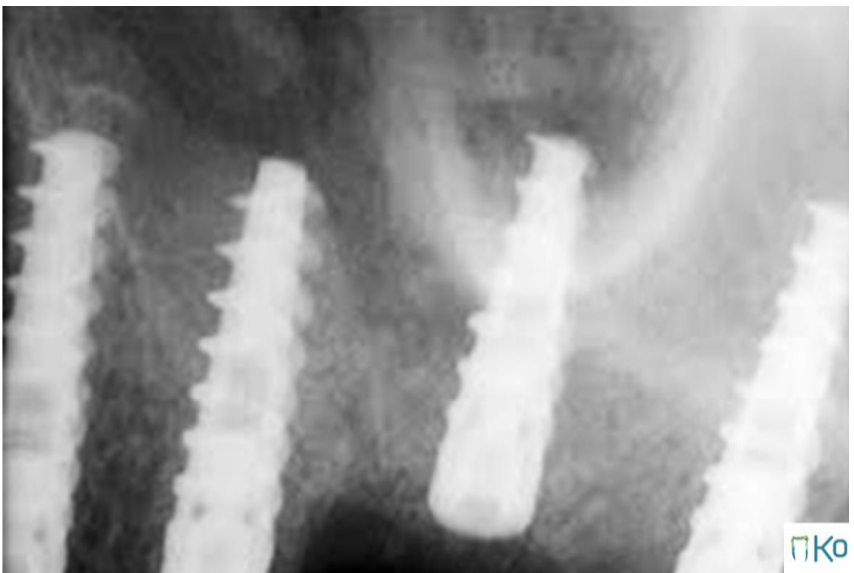
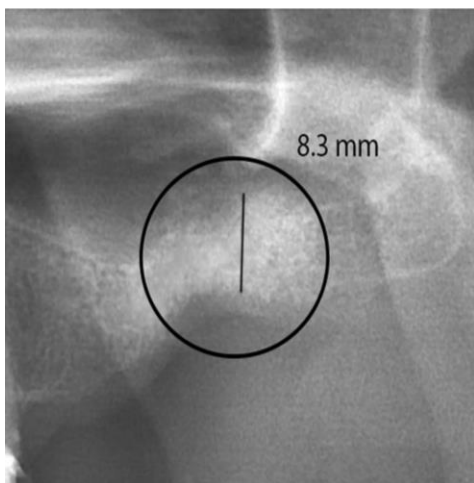
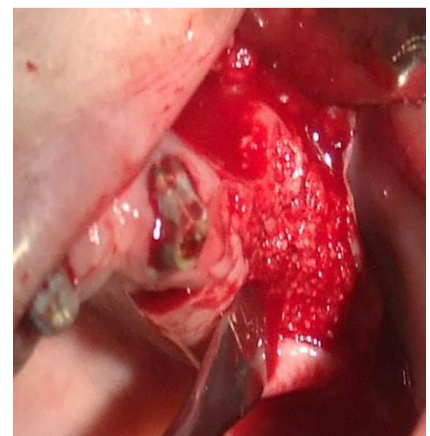
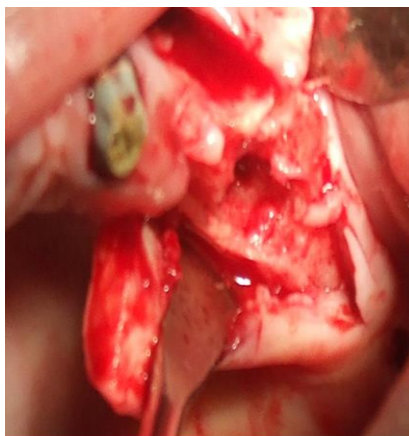
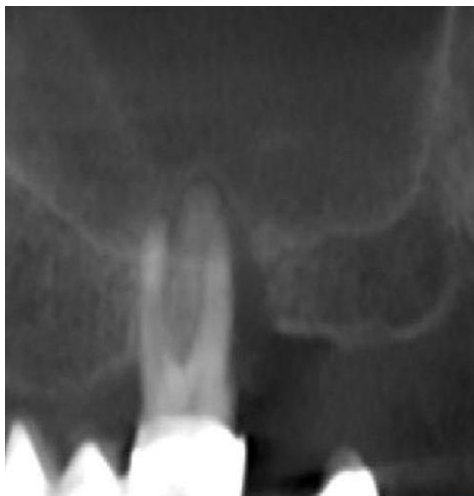
Grafting the sinus (Sinus Lifting)

Case description: Chronic periodontitis and endo-perio involvement of tooth #26. Extraction of tooth #26 exposed the sinus to the root canal (rupture of Schneiderian membrane). The tooth dentin particles were grafted through the roots into the sinus and ridge was augmented. The soft tissue was well sutured using a PRF membrane.

Results: Two month after grafting, bone height of 8.3 mm was achieved at its lowest point. Four implants were placed at this stage. **In conclusion, the affinity of osteogenic cells to autologous dentin made it possible to insert implants 3 month after closed sinus grafting.**



Two months after grafting

Three months after grafting