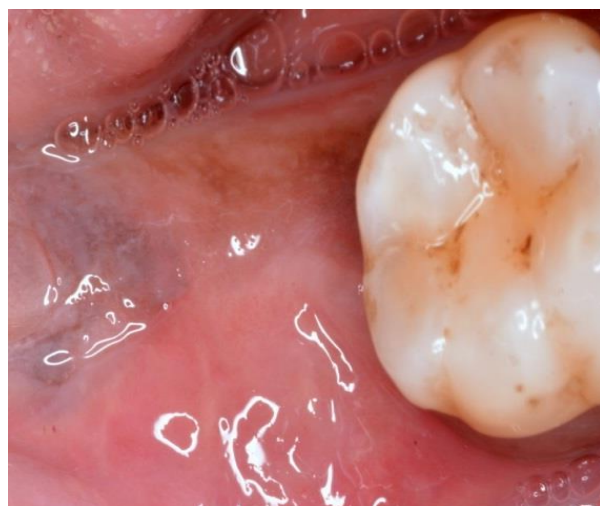
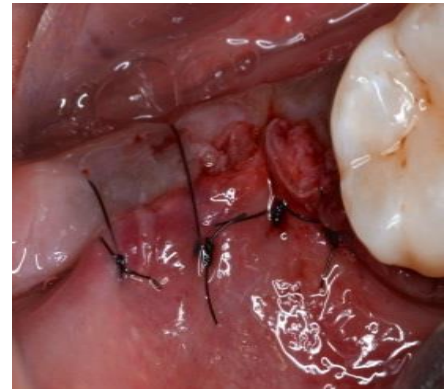
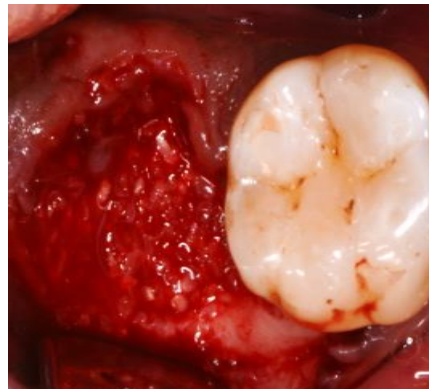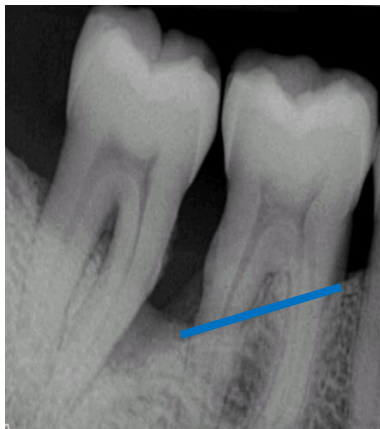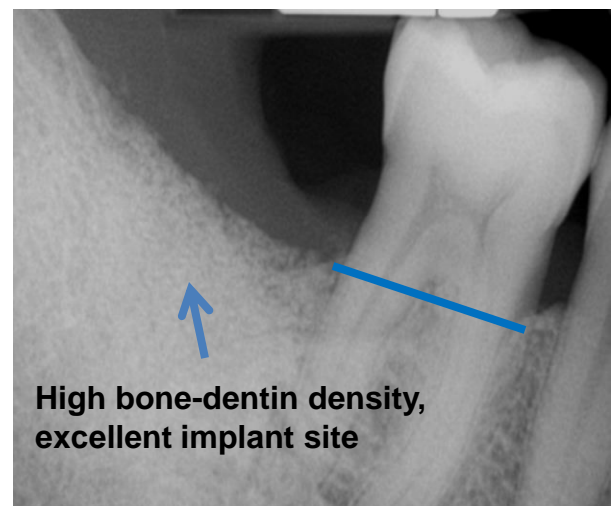
Saving the proximal tooth by augmenting alveolar ridge

Case description: Deep intrabony pocket defect and bifurcation involved tooth #37. Tooth was extracted. Roots ground and grafted. See bone level one month later.

Results: Tooth #36 was preserved and supported due to an effective autologous grafting procedure. **AUTOLOGOUS DENTIN GRAFT OF EXTRACTED TOOTH IMPROVES SIGNIFICANTLY BONE LEVEL OF THE PROXIMAL TOOTH**



2 weeks after grafting



1 month after grafting